

# Restoration of an “At Risk” Tooth

Replacing an old amalgam with a fiber mesh and a nano-composite.

By Grant T. Chyz, DDS

**W**hen is the right time to replace an old amalgam? Classic reasoning would require replacement when recurrent decay is present, if the old restoration cracks, or if the tooth fractures or develops symptoms (classic cracked-tooth syndrome). Cosmetic concerns may hasten this process when the black cast of the filling is undesirable to the patient, and some patients may seek removal of their metal fillings for esthetics or perceived health benefits. But one area that has received little attention in the literature concerns the treatment of incomplete cracks or fractures in asymptomatic teeth.

When an asymptomatic old amalgam filling is treatment planned for replacement, stained or (subjectively) “significant” marginal ridge cracks should put one on alert.<sup>1</sup> If the crack is only in enamel, it may be insignificant and filling replacement can proceed as planned. If, however, the crack extends completely through the marginal ridge (including the dentin supporting the marginal ridge), the cracked section can be removed and the tooth can still be restored with a direct restoration. Think of this as a fractured marginal ridge or proximal box. If the cracked marginal ridge extends significantly onto or across the pulpal floor, full coverage is called for.

Full coverage for an asymptomatic tooth with a true pulpal floor crack offers the possibility of avoiding endodontic complications or worse.

When this author encounters an asymptomatic tooth with pulpal floor cracks, he incorporates a fiber/composite laminate directly over the crack, to “span” the crack and provide additional support that composite alone may not provide. In addition, all teeth with significant pulpal floor cracks are treatment planned for crowns. This article presents a case that highlights one method to restore structurally compromised teeth. In this case, the third generation of the Filtek™ Supreme (3M ESPE, www.3mespe.com) line of nano-filled composite is used with additional structural support gained from a layer of Ribbond THM (Ribbond Inc, www.ribbon.com), laminated intimately with the pulpal floor of the tooth.

## A Unique Restorative

When replacing amalgam restorations, the clinician has a valuable opportunity to use a more esthetic and lifelike bonded material, such as a composite that incorporates nano-fillers into the resin matrix. This technology is found in the Filtek Supreme line of composites, which are unique nanocomposites. These restoratives are created using both individual nanoparticles and clusters of these particles, termed nanoclusters—a combination that gives the material several unique characteristics.

The restorative’s nanoclusters are lightly sintered, allowing them to break apart during the wear process. This property allows the restoration to retain its polish after wear, since individual nanometer-sized particles can be broken off the clusters without affecting the overall appearance of the restoration. Hybrid restoratives, on the other hand,

use both hybrid filler particles with nanoparticles or fumed silica. When these materials are subjected to wear, large particles can be plucked from the matrix, dulling the restoration’s polish.

As an alternative to hybrid restoratives, microfill composites are also known for their polish retention, but are often compromised in terms of strength. The bond between a microfill’s resin matrix and the prepolymerized “organic filler” matrix creates a weak link for these materials. Evidence shows that microfills are subject to fracture under stress and fatigue along lines between these particles.<sup>2,3</sup> They have also been shown to break down marginally under occlusal loading more than hybrid composites.<sup>4</sup>

A nanocomposite material is able to offer both the polish of a microfill with the strength of a hybrid. No prepolymerized filler is used in this material, and its filler loading is higher than that of typical microfills, which results in greater strength. The material’s high filler loading and advanced resin matrix enables outstanding compressive strength, flexural strength, diametral strength, and fracture toughness. Coupled with its polish retention, this makes the product truly universal, with the esthetics needed for anterior treatments, as well as the strength required in posterior regions.

The newest generation of this material, 3M™ ESPE™ Filtek Supreme Ultra Universal Restorative, follows the performance record of Filtek Supreme and Filtek Supreme Plus. The new incarnation builds on the esthetic and functional properties of its predecessor, offering an expanded range of body shades and providing more options for single-shade restorations. The polishability has been improved as well, with the dentin, body, and enamel shades now polishing just as nicely as the translucent shades, and all shades offering polish retention of a

microfill. Additionally, the new product offers improved life-like fluorescence.

## Fiber Reinforcement as Part of the Restorative Process

Ribbond is an ultra-high molecular weight polyethylene material that is plasma-treated for bonding and woven into a lock-stitch weave. The material adapts well to tooth structure when prepared as described in this article. It can reduce polymerization shrinkage, act as a crack arrester and crack deflector (much as the dentino-enamel junction can), and it can help distribute stress over a larger area.<sup>5</sup>

Lining the pulpal floor with Ribbond has been shown to increase the microtensile bond strength of the restoration and reduce adhesive failure in high C-factor preparations.<sup>6</sup> In addition, Ribbond has been shown to increase fracture resistance in cracked teeth as well as change the mode of failure of some of these teeth.<sup>7,8</sup>

In situations where tooth structure is compromised, such as high C-factor cavities, undermined cusps when full coverage is impossible and for teeth with pulpal floor cracks, the use of fiber reinforcement may provide a clinically significant benefit to the patient.

## Case Presentation

The patient presented with signs of recurrent decay with mesial and distal enamel cracks on tooth No. 12 that suggested a heightened risk of internal cracking (Figure 1 and Figure 2). While the patient was looking at the intraoral photograph of the tooth, the hygienist explained that treatment of teeth that exhibit cracked “walls” (the term the author and his team uses during discussion with patients) can be completed with a composite filling if the tooth does not have cracks extending into the



**GRANT T. CHYZ, DDS**  
Private Practice  
Seattle, Washington

“floor” (also the term the author and his team uses with patients). If, however, there was a cracked “floor,” the filling would reinforce the tooth and a crown would be recommended (Figure 3 through Figure 5). The patient agreed to have the filling replaced despite a lack of a clinical catch and without radiographic decay present, with the hope that her tooth was not cracked. The patient understood that crowning the tooth would be recommended if it showed internal (pulpal floor) cracks.

The treatment plan called for removal of the old amalgam under a rubber dam, removal of any recurrent caries, and inspection of the remaining tooth for structural integrity. Definitive treatment would be a composite restoration using Filtek Supreme Ultra universal restorative if the dentin was not cracked. If internal (dentinal) cracks were found, treatment would include a composite build-up over a layer of Ribbond THM that would be laminated to the dentin (spanning any cracks), and a 3M™ ESPE™ Lava™ zirconia/porcelain crown.

To remove the amalgam and determine the proper course of action, the tooth was anesthetized with one carpule of Septocaine® (Septodont, www.septodont.com) and a rubber dam was placed. The amalgam was carefully removed to minimize vibration trauma. A new DENTSPLY Midwest 1157 bur (www.dentsply.com) was used in an electric handpiece at 200,000 rpm (Figure 6). Recurrent decay was removed with the 1157 bur at 50,000 rpm (Figure 7). The remaining stained dentin was hard and did not hold caries detector stain. The tooth was then inspected for structural integrity. It was determined that the mesial and distal marginal ridges were cracked and were partially responsible for the recurrent decay found after removing the amalgam (Figure 8). A close inspection of the pulpal floor of the tooth under 5x magnification did not reveal any dentin cracks. In this case, the fact that the cracks were limited to the mesial and distal enamel walls represented the best possible situation for this tooth. Without internal cracks, there was an opportunity to avoid a crown, and the long-term prognosis for the tooth is excellent. *Note: If the pulpal floor had been cracked (as seen in Figure 2), the proximal walls would have been thinned, but not removed. Ribbond/Supreme reinforcement would have been*

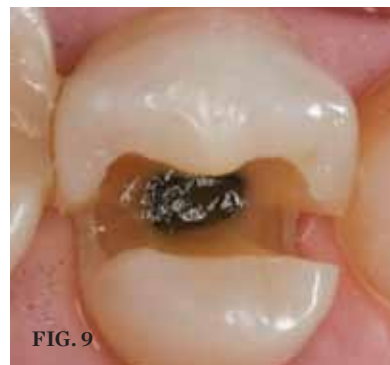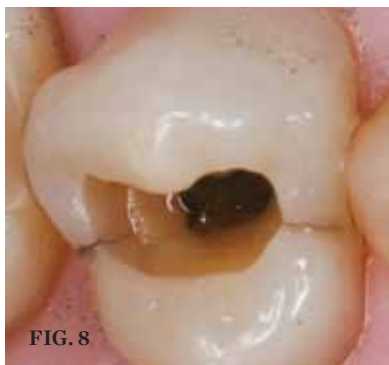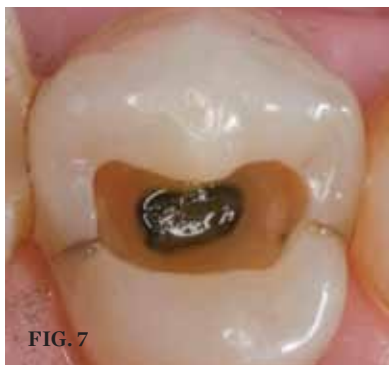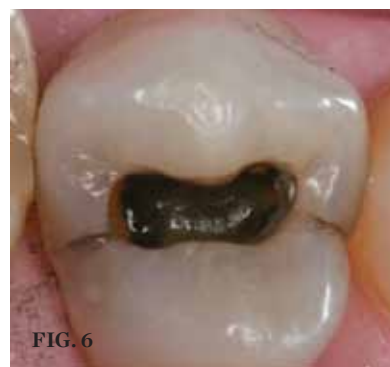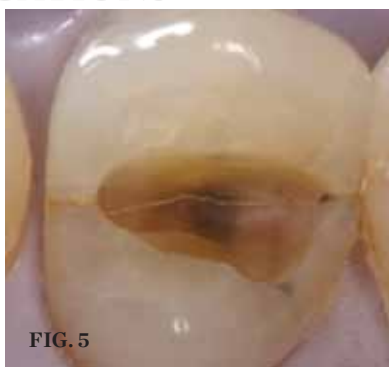
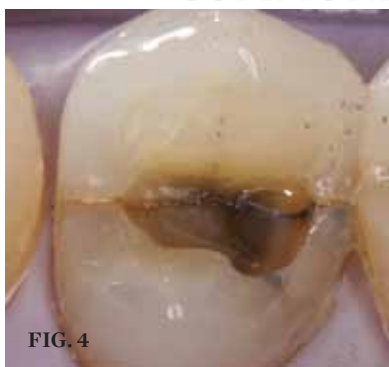
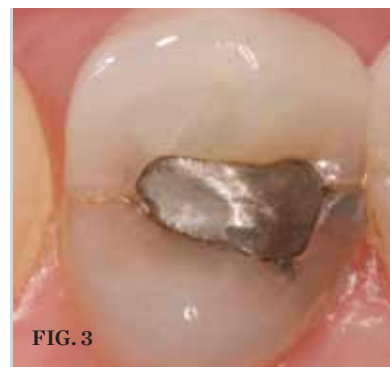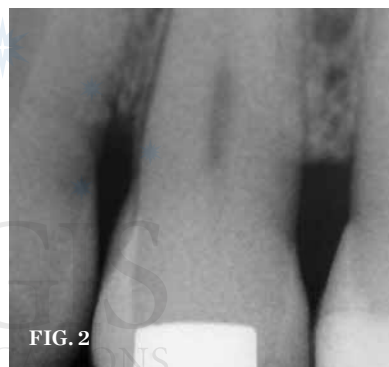
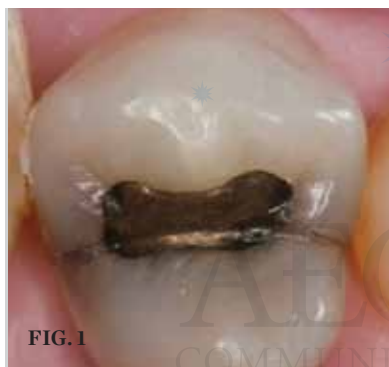*placed and a crown would have been recommended. The remaining thin proximal walls would be removed during the crown preparation. This reduces trauma to the tooth and changes the treatment plan from a 3-surface composite to a 1-surface composite.*

The cracked marginal ridges were prepared as conservative boxes using the same round-ended bur, resulting in a fairly narrow (buccal to lingual) but deep cavity preparation with round internal line angles (Figure 9). The depth of the preparation, along with the narrow buccal-lingual dimension, resulted in a high C-factor restoration with increased risk of cusp failure in the future. To minimize the influence of the C-factor and shrinkage stress, and to make the tooth more crack-tolerant in

the future, a polyethylene fiber, Ribbond, was laminated to the pulpal floor and axial walls of the preparation.

To perform this procedure, the axial walls and marginal ridges were first restored. A standard Tofflemeyer matrix band was selected instead of a sectional matrix because the proximal boxes were fairly narrow and lingual to the contact area (Figure 10). The tooth was etched for 15 seconds and then rinsed, after which excess water was suctioned away. Two layers of 3M™ ESPE™ Adper™ Single Bond Plus Adhesive were applied according to manufacturer instructions. After evaporating the solvent with a light stream of air for 5 seconds, the bonding agent was polymerized for 10 seconds. The axial walls were restored with two increments of Filtek Supreme Ultra

universal restorative. Shade A3B was used for the first cervical increment and A1E was used to form the marginal ridges on the mesial and distal. Each increment was cured for 10 seconds (Figure 11). The matrix band was removed and the Ribbond was selected and prepared for bonding. The author selected 4 mm Ribbond THM and cut off a 5-mm section. The fiber was then wet with 3M™ ESPE™ Adper™ Scotchbond™ Multi-Purpose Plus Adhesive (an unfilled resin without solvent or water) on a paper pad. Next, a small amount of shade A3B Filtek Supreme Ultra universal restorative was pressed into the fiber. The resultant Ribbond-Supreme fiber was placed on the tooth and adapted closely to the dentin without suffering pullback (Figure 12 and Figure 13).



**PREOPERATIVE CONDITION (1.)** Tooth No. 12 showed signs of recurrent decay with mesial and distal enamel cracks. **(2.)** The pretreatment radiograph. **FULL CRACK EXAMPLE (3. THROUGH 5.)** Pulpal floor cracking (as in this asymptomatic tooth) would have changed the treatment plan and the prognosis. **PREPARATION STEPS (6.)** The amalgam was carefully removed. **(7.)** Recurrent decay was removed. **(8.)** Cracks extended down the proximal walls of the tooth but did not extend onto the pulpal floor. **(9.)** The marginal ridges were prepared as conservative boxes, resulting in a narrow but deep preparation with round internal line angles.

After fiber placement, a layer of A3B restorative was placed, carefully adapted, and cured. Finally, a layer of A1E restorative was placed, adapted, sculpted into shape, and cured (Figure 14). The restoration was finished with a series of 3M™ ESPE™ Sof-Lex™ Contouring and Polishing Discs for the axial walls (Figure 15). Next, a super-fine interproximal diamond was used to refine the shape sculpted into the occlusal surface (Figure 16). A rubber cup was used for initial polishing, followed by a brush with polishing paste (Figure 17 and Figure 18). As previously mentioned, Filtek Supreme Ultra polishes easily to

an enamel-like luster and blends nicely with the adjacent tooth structure (Figure 19). After removal of the rubber dam, the occlusion was checked. At the conclusion of treatment, the patient was given the opportunity to see what was found during treatment with a series of intraoral images. The patient was happy that her tooth was not cracked internally, and with the improved appearance of the tooth as well as the fact that she would not need a crown.

### Discussion

This case demonstrates the use of fiber reinforcement in a high C-factor

preparation. The author encourages carefully designed research regarding the treatment of teeth with potential structural cracks in enamel, or incomplete cracks in dentin.

Craze lines are present in virtually all teeth. It is clear that treating a tooth because of a non-structural craze line is inappropriate. But if the craze line progresses to the dentino-enamel junction and becomes more substantial (granted, this is an arbitrary and subjective determination), there is a risk of propagating into dentin. Once a tooth has a crack into or across the pulpal floor, the long-term prognosis for the

tooth becomes less clear. Most dentists would agree that these teeth should be crowned. Some teeth with pulpal floor cracks become necrotic, and some are lost if the crack propagates into the root.

### Conclusion

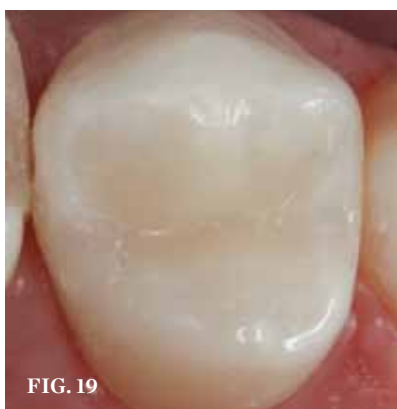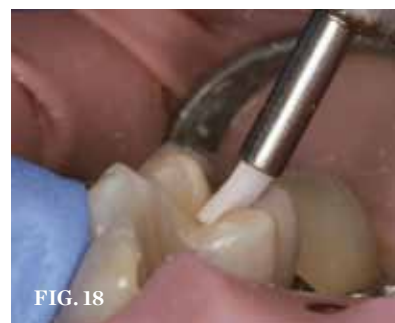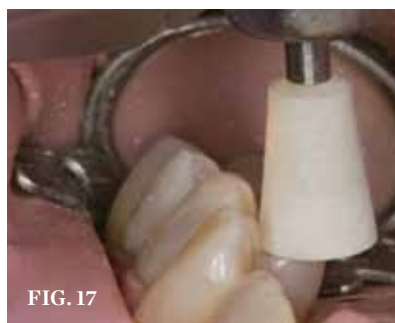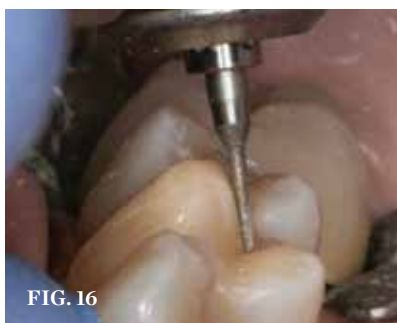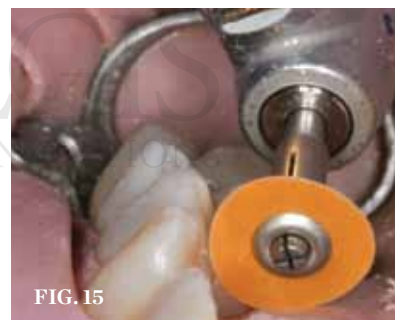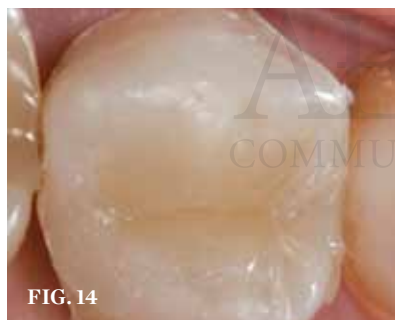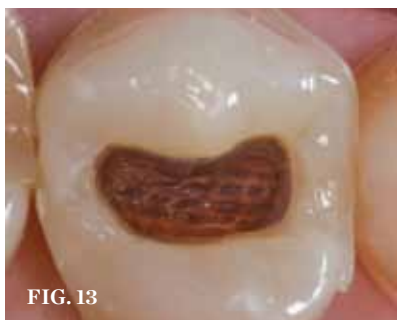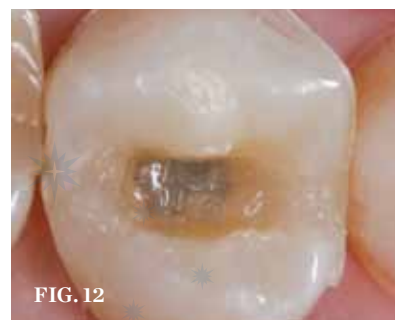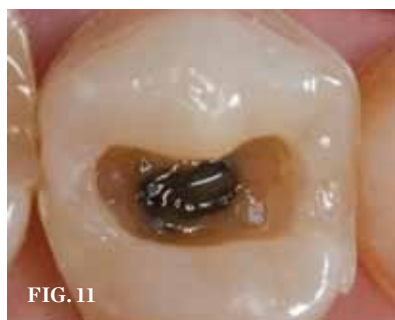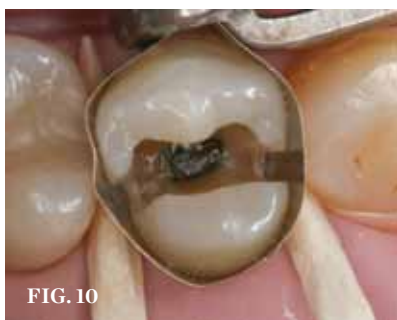The use of fiber to reinforce structurally compromised teeth needs more research, but holds promise. Fiber can increase the damage tolerance of a tooth. It can be used to provide additional support to weakened cusps and to span cracks. Fiber may also reduce the effective shrinkage of the restoration (by taking up space). Combining careful technique with an excellent restorative material and appropriate proactive treatment can improve the long-term prognosis of a tooth. Finally, waiting for symptoms or catastrophic failure for an “at risk” tooth may not be in the best interest of the patient, who is hoping to keep his or her teeth for a lifetime.

### Disclosure

Dr. Chyz is a stockholder in and an occasional unpaid consultant for 3M ESPE.

### References

1. Clark D, Sheets S, Paquette J. Definitive diagnosis of early enamel and dentin cracks based on microscopic evaluation. *J Esthet Restor Dent.* 2003;15(7):391-401.
2. Lambrechts P, Vanherle G. Structural evidences of the microfilled composites. *J Biomed Mater Res.* 1983;17(2):249-260.
3. Drummond JL. Cyclic fatigue of composite restorative materials. *J Oral Rehabil.* 1989;16(5):509-520.
4. Ferracane JL, Condon JR. In vitro evaluation of the marginal degradation of dental composites under simulated occlusal loading. *Dent Mater.* 1999;15(4):262-267.
5. Karbhari VM, Strassler H. Effect of fiber architecture on flexural characteristics and fracture of fiber-reinforced dental applications. *Dent Mater.* 2007 Aug; 23(8):960-8.
6. Belli S, Donmez N, Eskitascioglu G. The effect of c-factor and flowable resin or fiber use at the interface on microtensile bond strength to dentin. *J Adhes Dent.* 2006;8(4):247-253.
7. Garpisjo S, Ballo A, Lassila L, Vallittu P. Fracture resistance of fragmented incisal edges restored with fiber-reinforced composite. *J Adhes Dent.* 2006;8(2):91-95.
8. Belli S, Cobankara FK, Eraslan O, et al. The effect of fiber insertion on fracture resistance of endodontically treated molars with MOD cavity and reattached fractured lingual cusps. *J Biomed Mater Res B Appl Biomater.* 2006;79(1):35-41.



**RESTORATION STEPS (10.)** A standard Tofflemeyer matrix band was selected instead of a sectional matrix because the proximal boxes were fairly narrow and lingual to the contact area. **(11.)** Filtek™ Supreme Ultra Universal Restorative was used for the first cervical increment and the marginal ridges on the mesial and distal. **(12.)** Ribbon THM 4 mm was prepared and the resultant Ribbon/Supreme fiber was placed on the tooth and adapted closely to the dentin without suffering pullback. **(13.)** Simulated fiber placement with color to help the reader visualize where the fiber was placed. Ribbon THM 4 mm covered the pulpal floor and extended slightly up the axial and proximal walls. **(14.)** After fiber placement, successive layers of Filtek™ Supreme Ultra Universal Restorative were placed and sculpted. **(15.)** A series of contouring and polishing discs was used on the axial walls. **(16.)** A super-fine interproximal diamond was used to refine the shape sculpted into the occlusal surface. **(17.)** A rubber cup was used for initial polishing. **(18.)** A brush with polishing paste completed the finishing. **(19.)** The Filtek™ Supreme Ultra Universal Restorative polished easily to an enamel-like luster and blended nicely with the adjacent tooth structure.